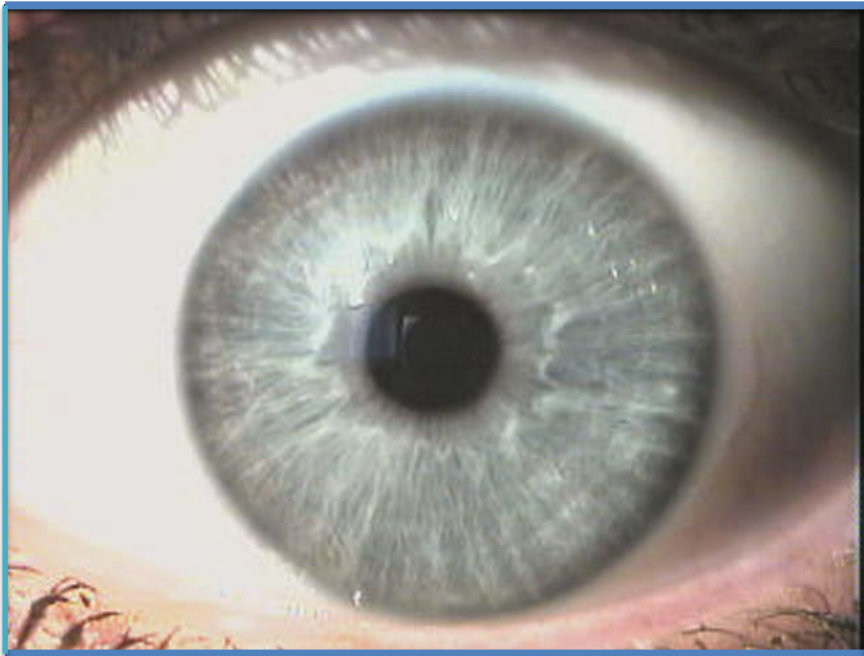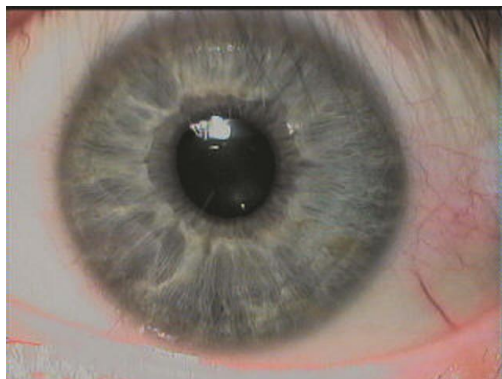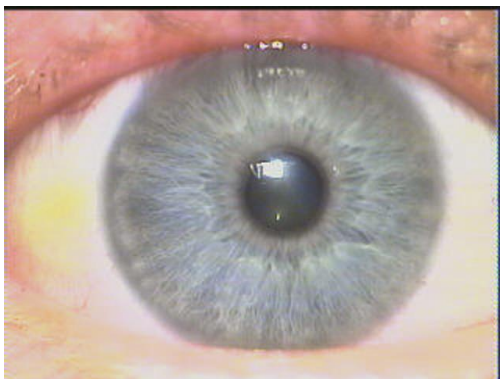
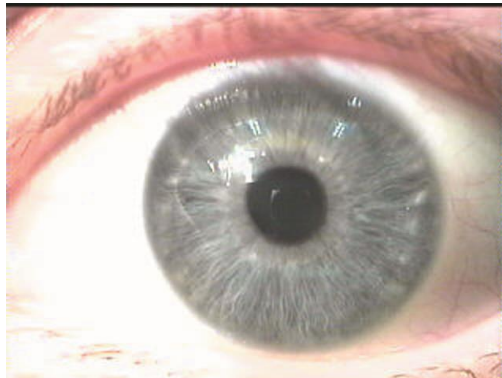
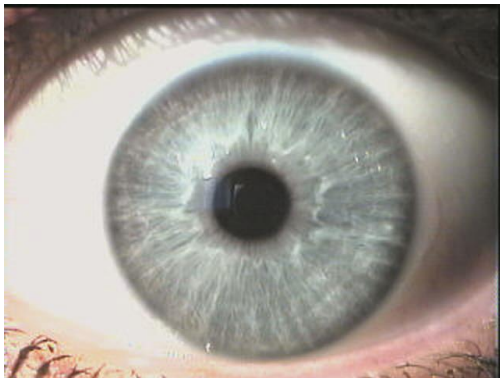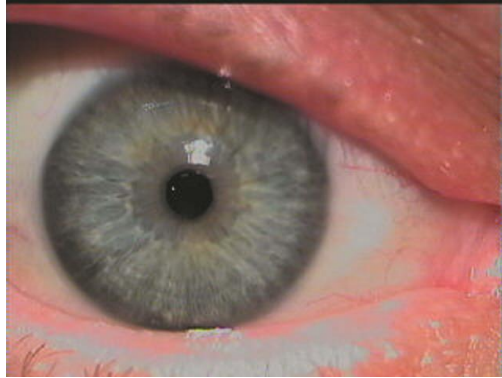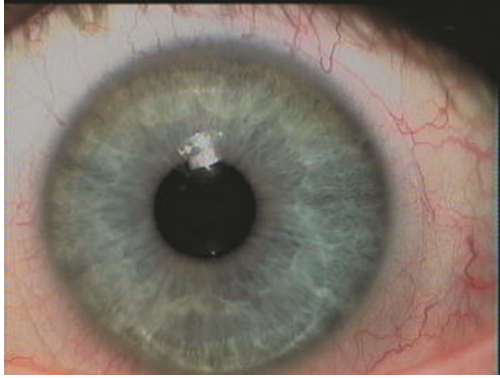


# PHOTOGRAPHS OF INDIVIDUAL GENETIC EYE CONSTITUTIONS

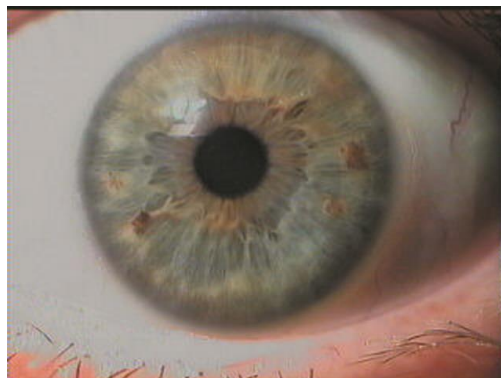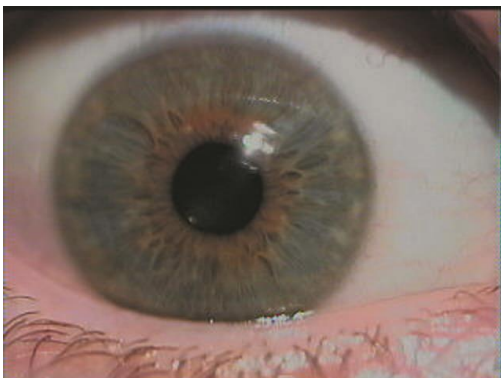
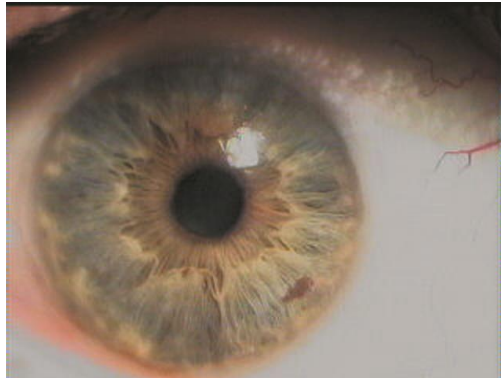
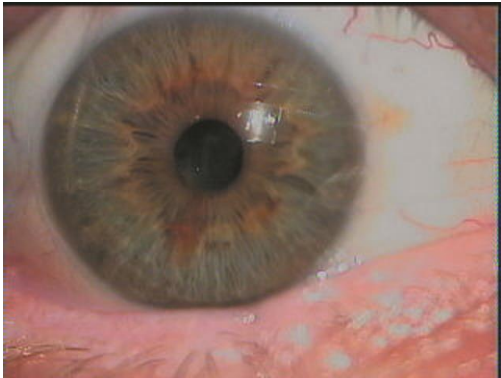
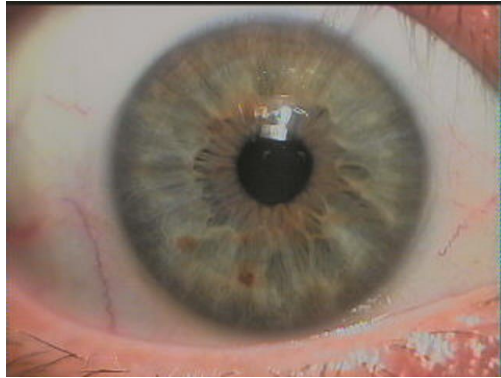
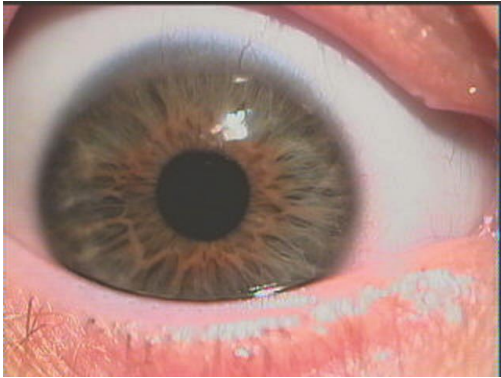
## **Blue-eye Types**



## Lymphatic Hyper-active

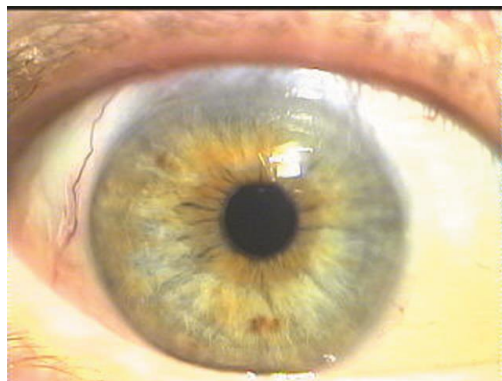
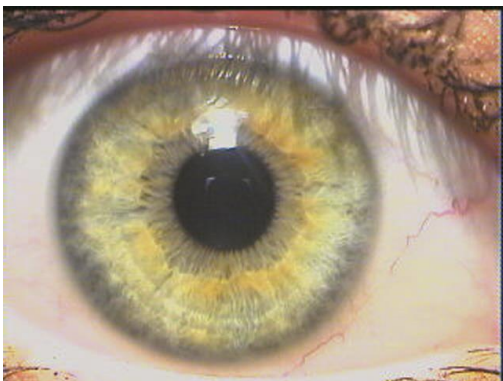
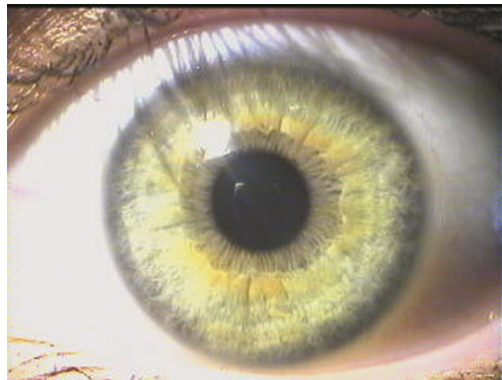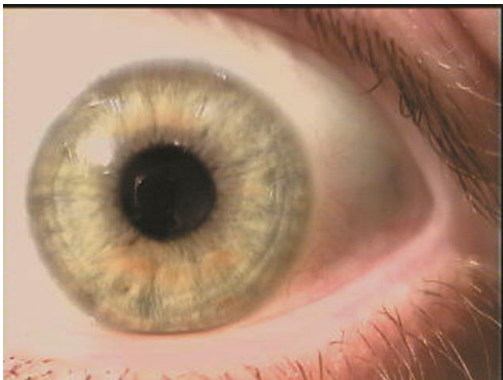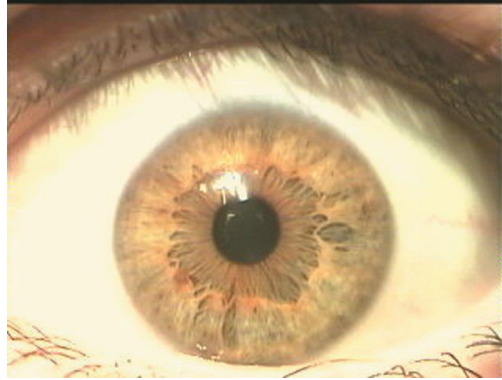
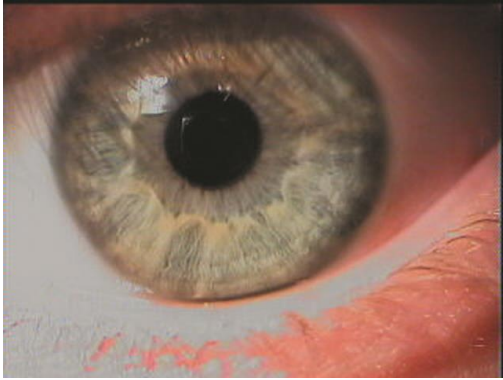


## Lymphatic Hypo-active

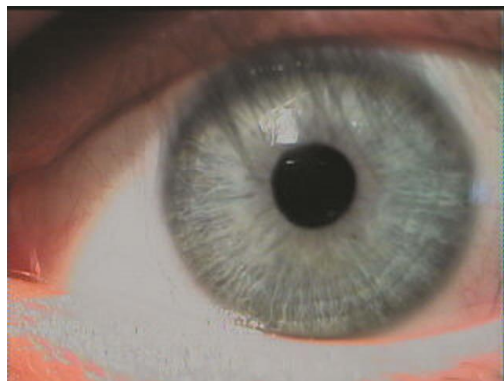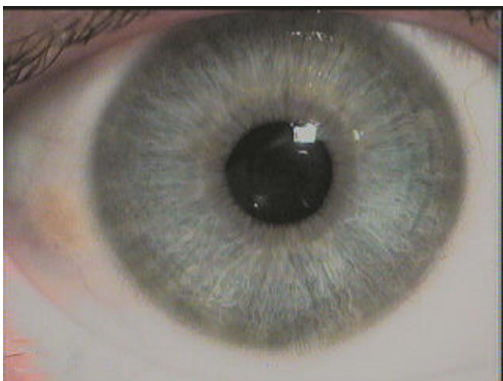
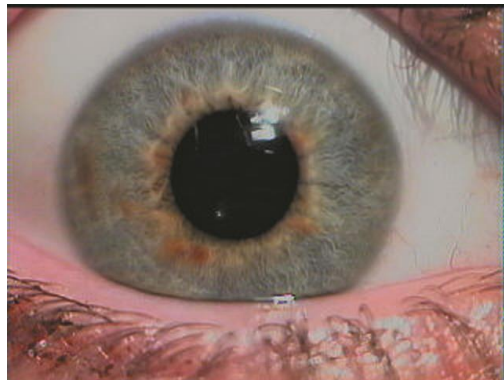
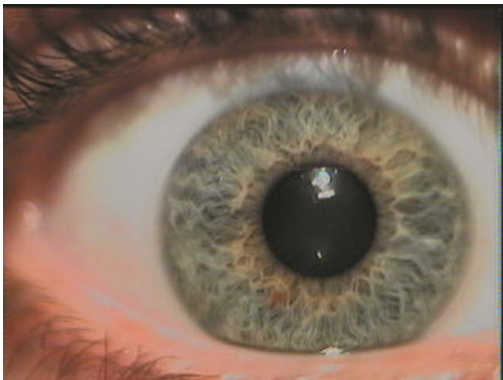
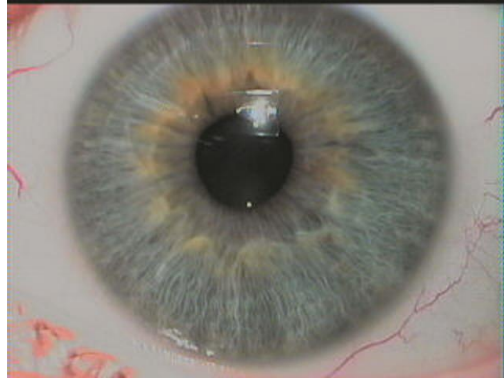
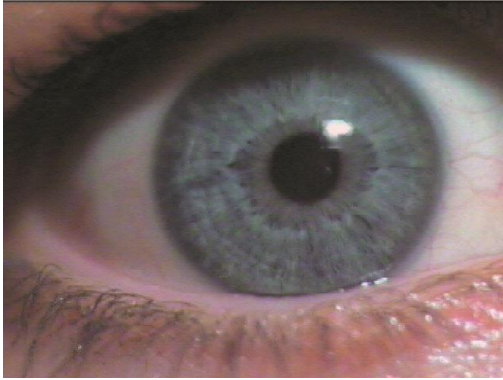




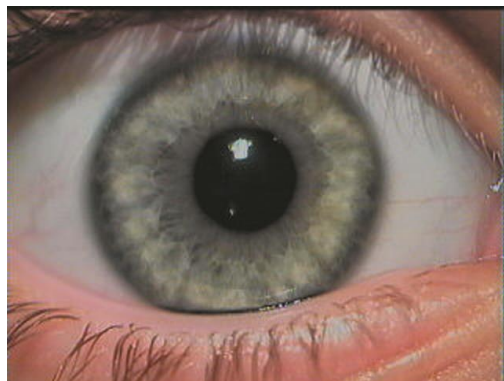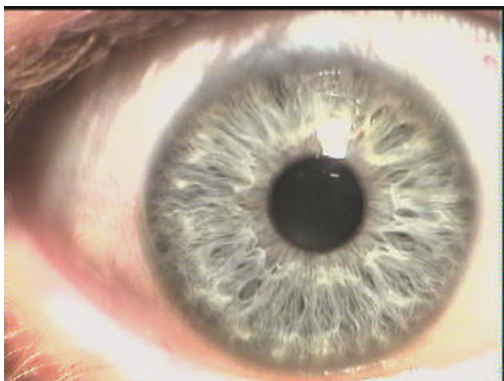
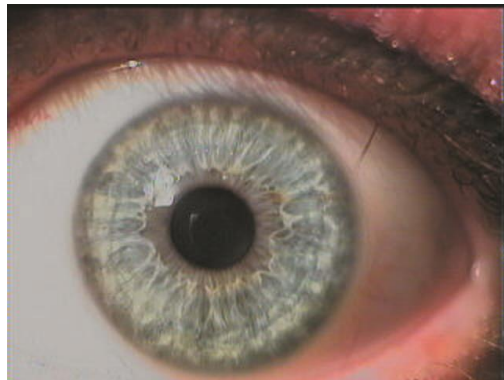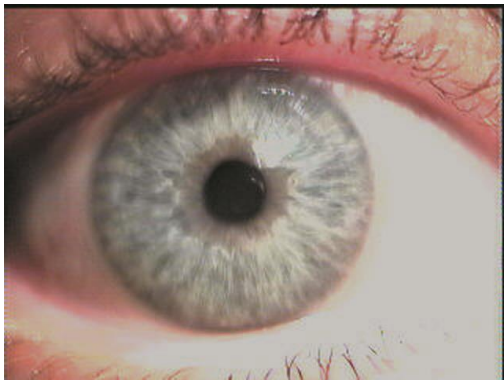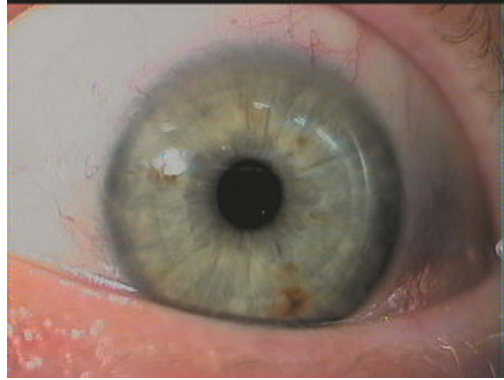
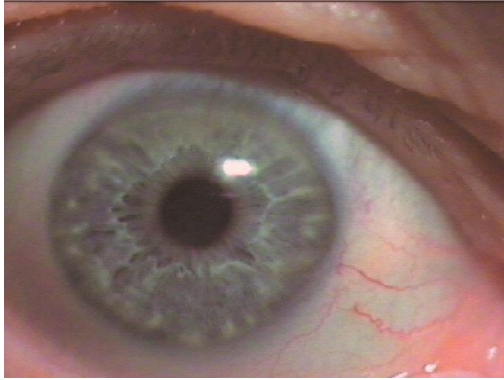
## Kidney Lymphatic



## Neurolymphatic

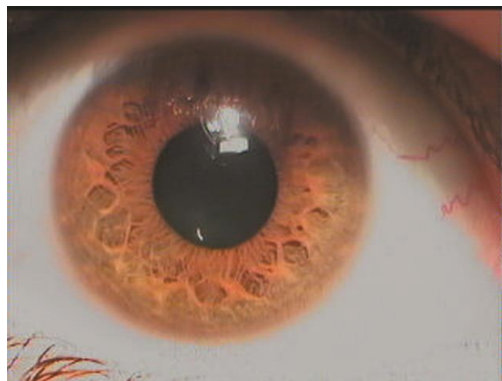
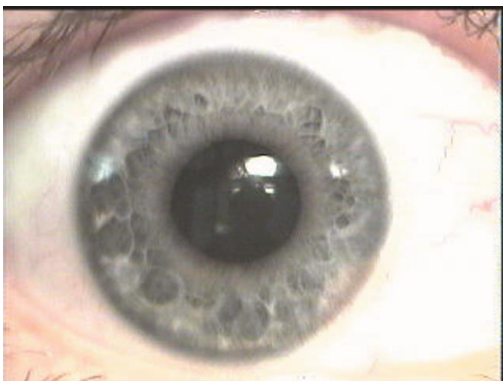
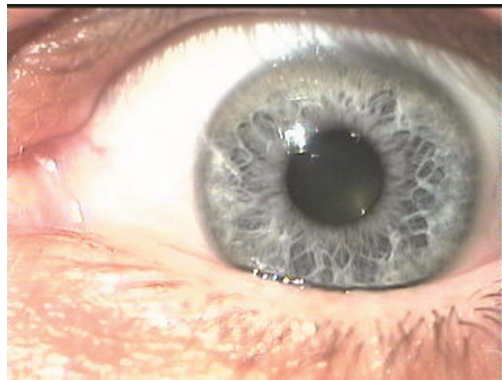
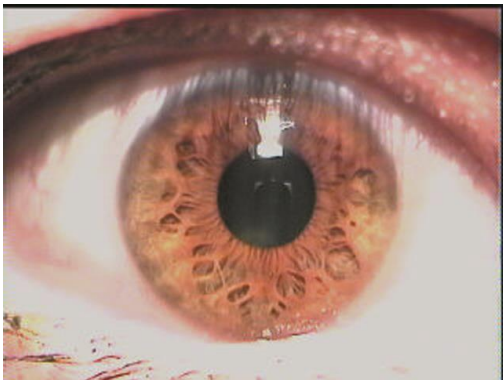
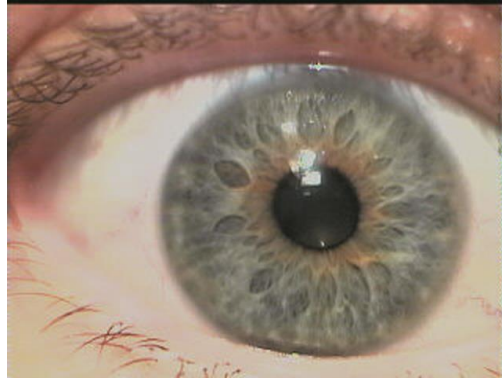
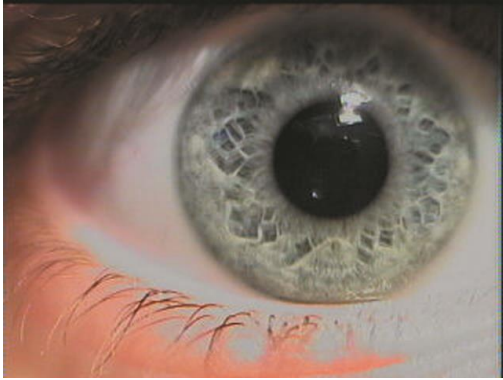

## Hydrolymphatic

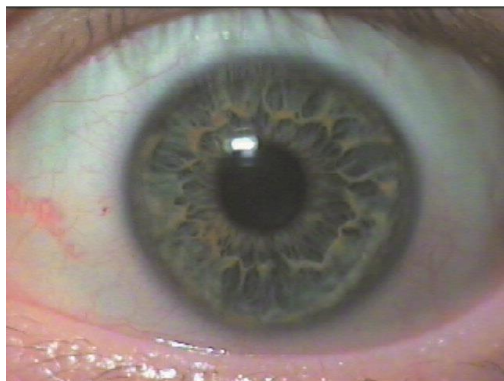
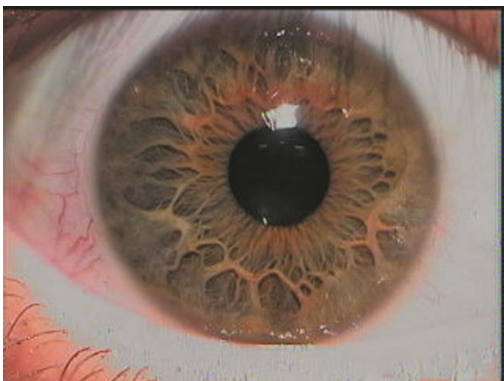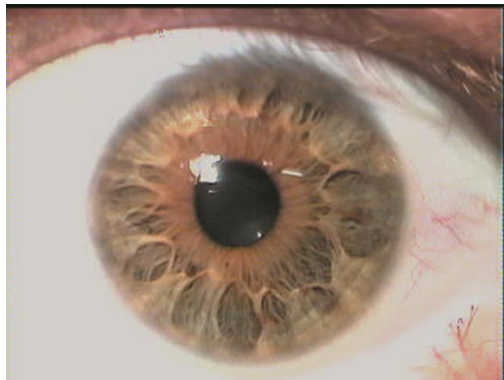
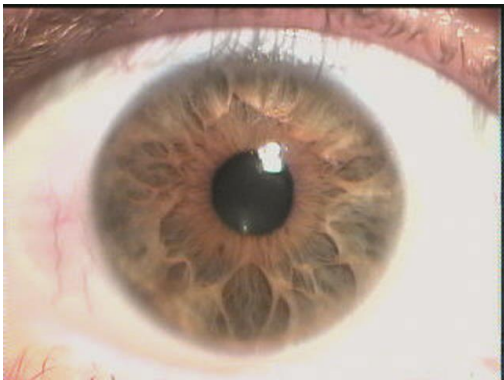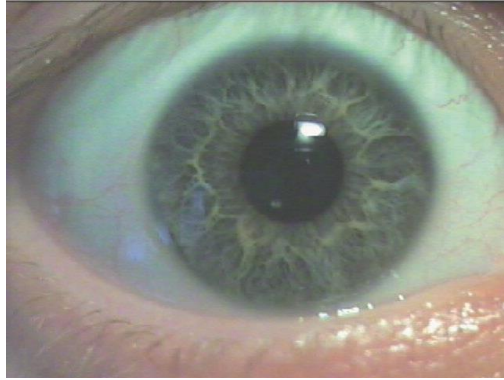
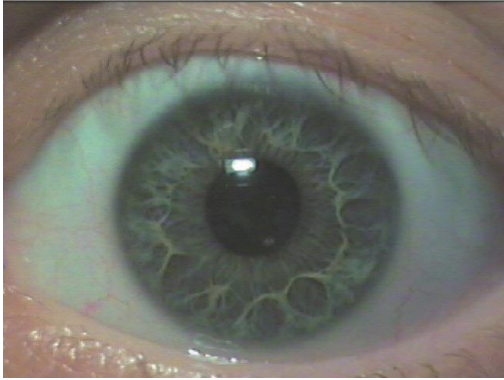




## Hormonal

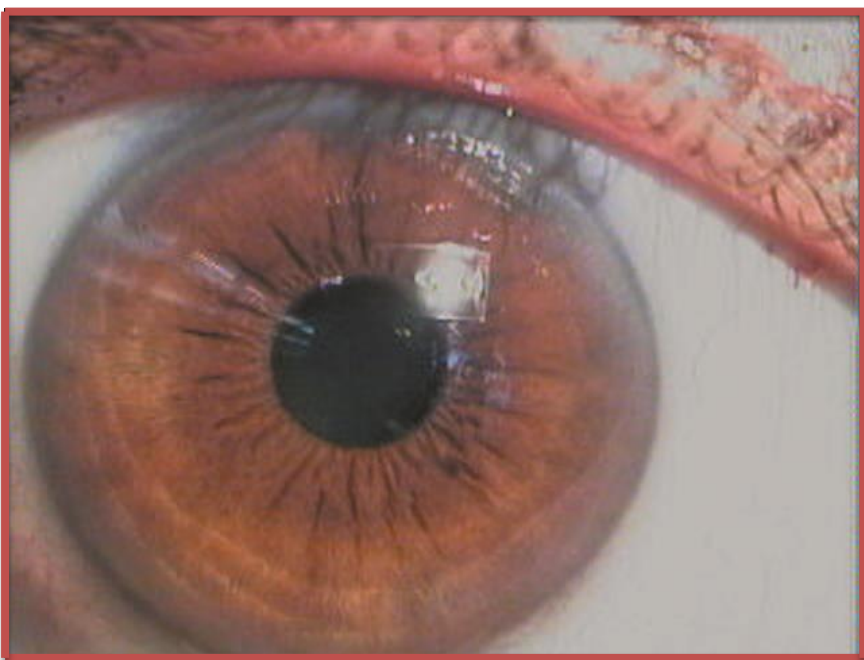


## Connective Tissue

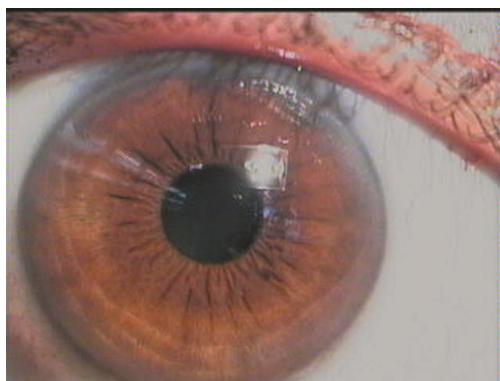
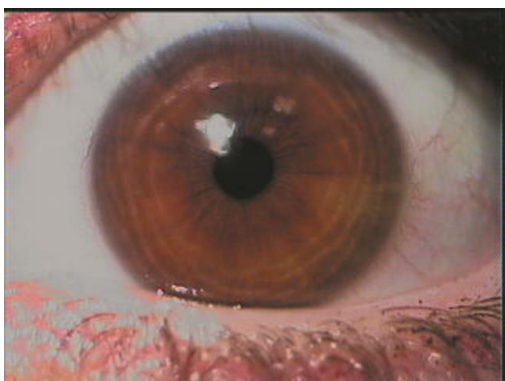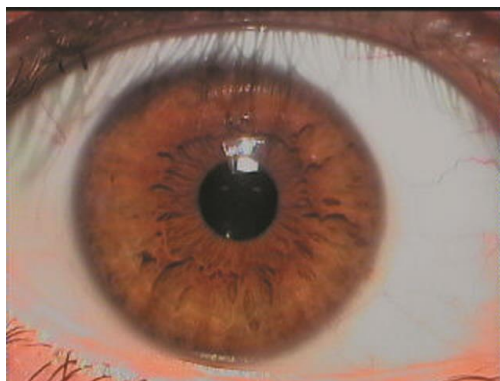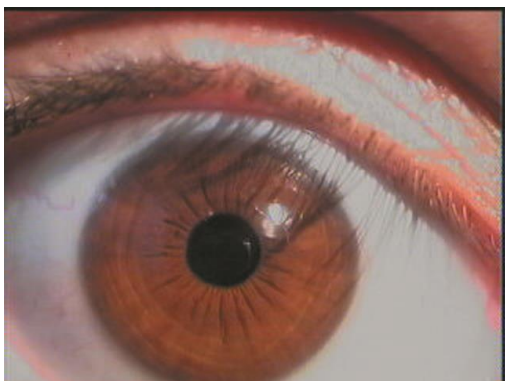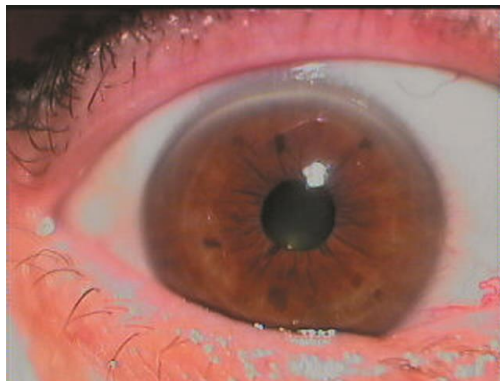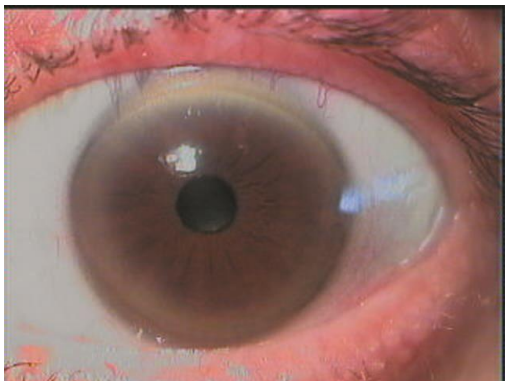




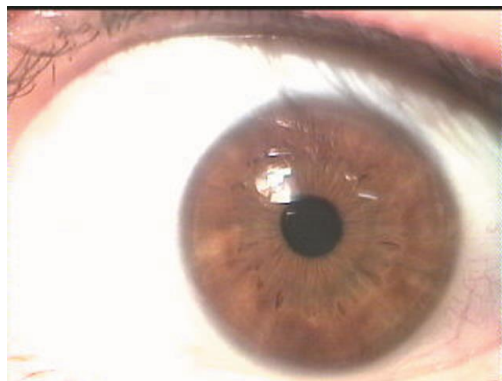
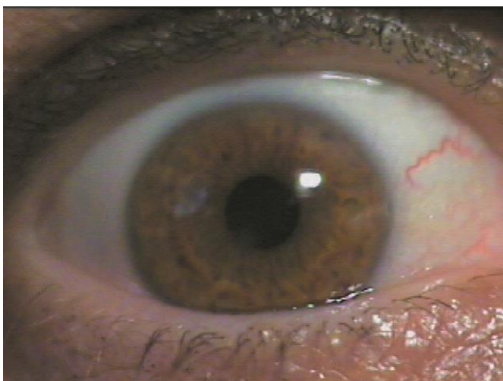
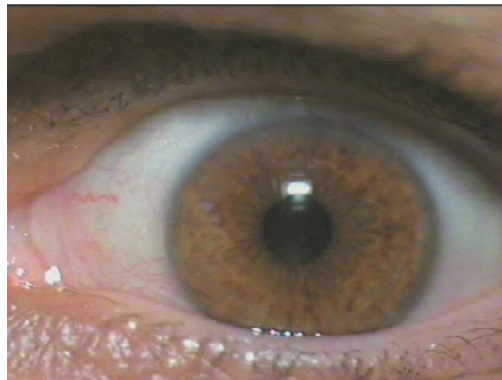
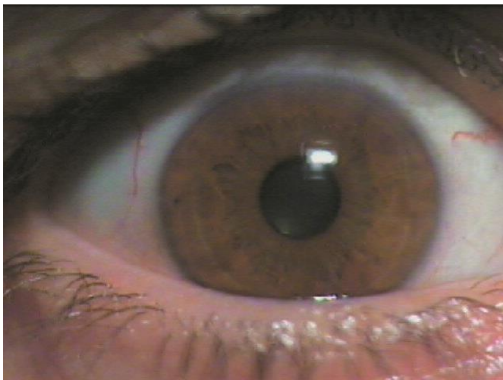
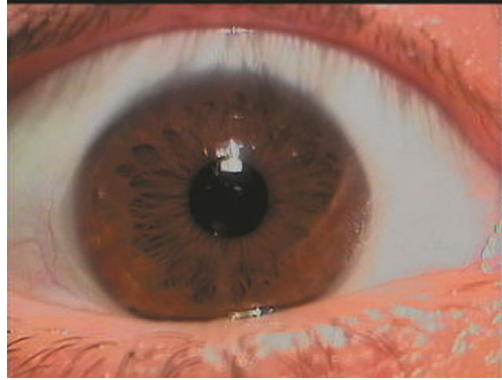
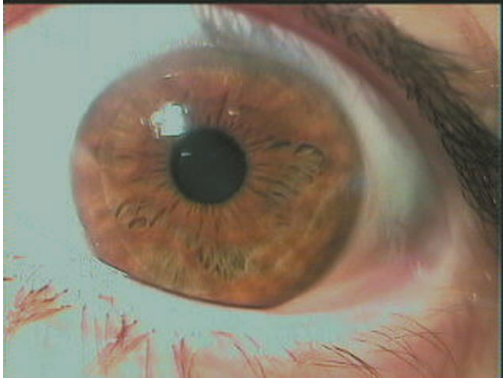## Brown-eye Types



## Hematogenous



## Plethoric





## Mixed

